Prosthodontics

Lec. 12 **د. غسان الطائي**

https://youtu.be/F2wax8D0POA

SELECTION OF ARTIFICIAL TEETH

A- Selection of anterior teeth

B- Selection of posterior teeth

Selection of anterior teeth:

Anterior teeth are primarily selected to satisfy esthetic requirements. Records of size, form and shade of teeth could be obtained from pre-extraction records which include:

1. Diagnostic casts with natural teeth
2. Pre-extraction photographs
3. Pre-extraction radiographs
4. Observation of teeth of close relatives
5. Preserved extracted teeth

Factors to be considered when pre-extraction records are not available:

A. Shade (color).
B. Size.
C. Form.

A. Shade:- Shade mean degree of darkness of the color. The yellow and gray are the basic shades, and the other shades varies in between.

The factors of shade selection:

1. Age.
2. Sex.
3. Complexion.
4. Patient preference.

1. Age:- The younger the patient, the lighter the color is preferred. The color of natural teeth darken with age because of deposition of secondary dentin, wearing away of enamel and external staining from oral fluids, foods or tobacco.

2. Sex:- The sex may effect color, it seems that females given brighter teeth than males.

3. Complexion:- The color of the face should harmonize the color of teeth. Lighter teeth are suitable for lighter skin, while darker teeth are suitable for darker skin. Although darker people with dark skin seemed to have very light teeth. This is because of contrast in the skin and tooth color.

4. Patient preference (method of pair comparison):- Show the patient the lightest and darkest shades, hold them against the patient lip and ask them to point to the one that they prefer. More than two or three shades should be selected and comparison between them would help in final right selection.

B. <u>Size:-</u>

To select size of anterior teeth we have to consider the following:

1. Length.

2. width.

3. Method of pair comparison.

1. Length:- The length of upper anterior teeth is controlled by:-

*** Inter-ridge distance.**

*** Length of upper lip:**

A. In short lip more than 2 mm seen from upper central incisor.

B. Medium lip 1-1.5 mm seen from upper central incisor.

C. Long lip nothing can be seen from upper central incisor, as seen in **Figure 1**.

* The length of lower anterior teeth should be with level of lower lip.

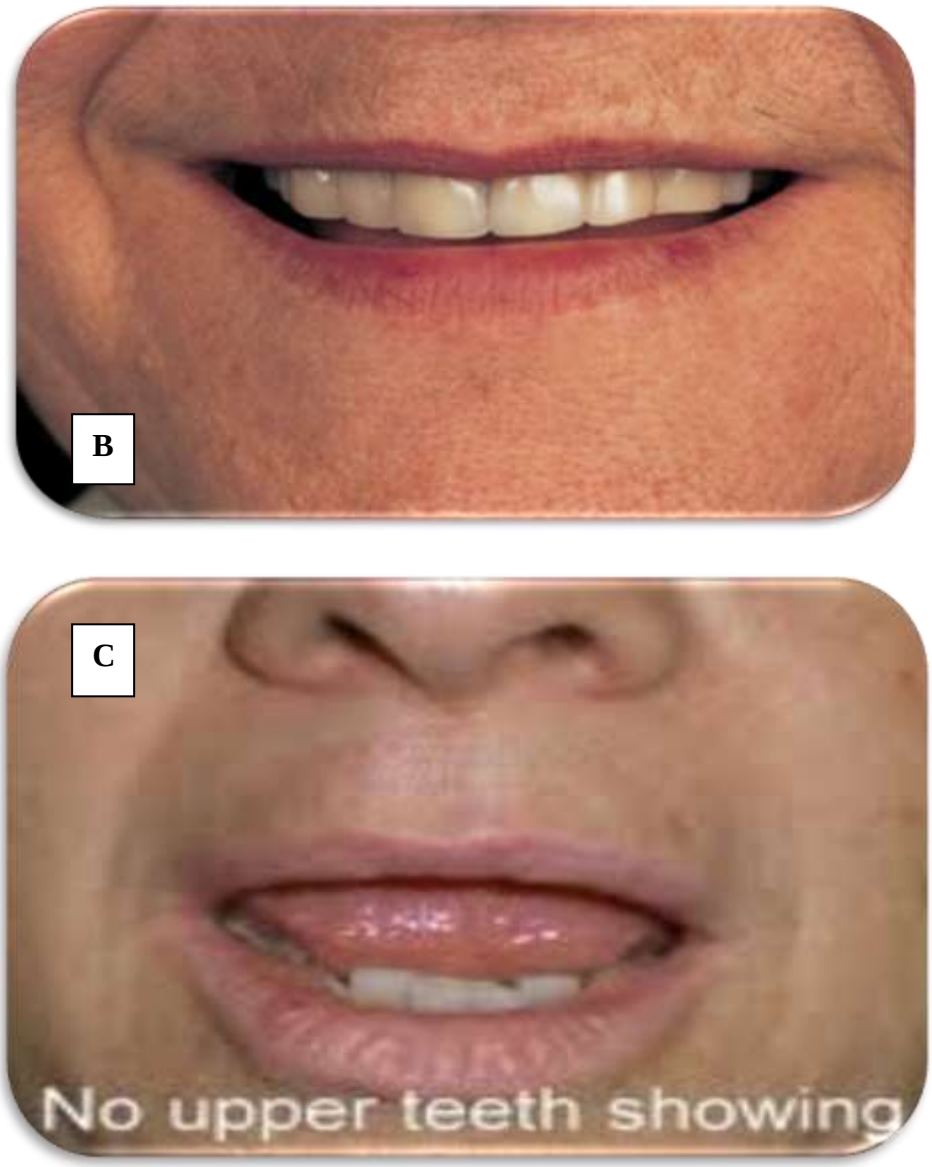

Figure 1: The length of upper lip were divided into: (A) short lip; (B) medium lip; and (C) long lip.

2. width:-

A. The width of upper central incisor equals approximately 1/16 of bi-Zygomatic width, and width of upper anterior teeth equal to 3.3 bi-Zygomatic width as shown in **Figure 2**.

Figure 2: Measurements on skulls indicate that width of natural central incisor.

B. The width from the tip of left canine to the right canine is almost equal to the width of the nose when measured in a straight line by a caliper **(Figure 3)**.

Figure 3: Cusp tip of upper canine coincide with outer border of the nose.

C. Width of the anterior teeth can be measured on upper occlusion rim depending on buccal frenum, corner of the mouth and canine eminence **(Figure 4)**.

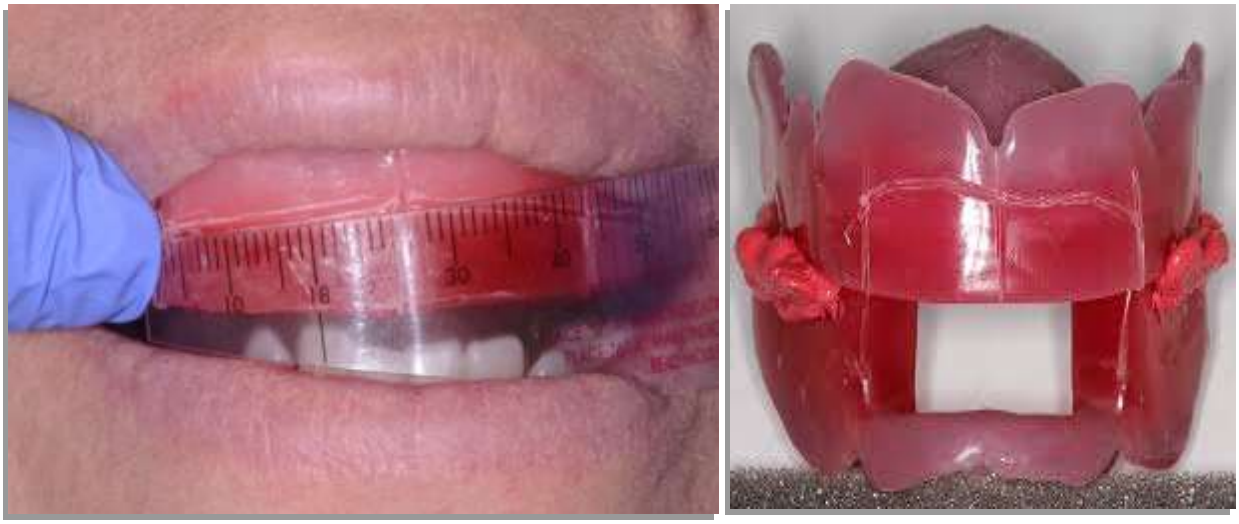

Figure 4: Measurements the width of the anterior teeth depending on buccal frenum, corner of the mouth.

3. Method of pair comparison:-

Use the method of pair comparison to assist the patient to decide what size of tooth they prefer. Set two different sizes of teeth on a piece of wax rope were placed under the upper lip, and find out which one the patient prefers. Two or three presentations may have to be made to reach a decision.

C. <u>Form</u>:- The form of anterior teeth depend on the following:

1. Face form.
2. Sex, age and personality.
3. Method of pair comparison.

1. Face form:-

- According to frontal out-line, face could be classified into square, ovoid and tapering. The upper central incisor form should be in harmony with patient face, as seen in **Figure 5**.

Figure 5: Form of artificial teeth chosen to be in harmony with the outline form of the patient's face.

- Profile of the face can be divided into:

Straight, convex and concave. The labial surface of upper central incisor viewed from the mesial aspect should be in harmony with profile of the face **(Figure 6)**.

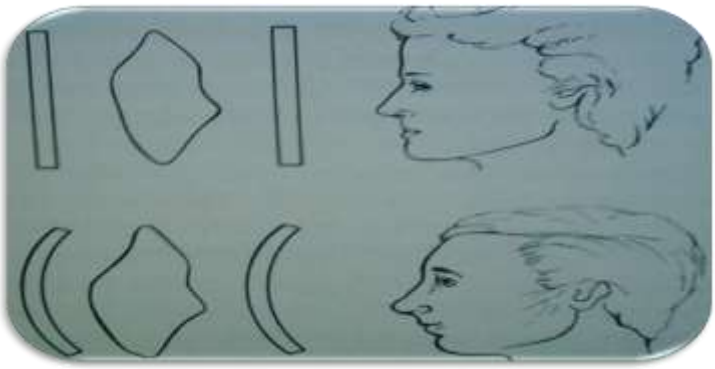

Figure 6: labial surface of teeth are in harmony with profile of the face.

2. Sex, age and personality:-

Sex: Masculine form is associated with square, cuboidal and angular form. While feminine form associated with more rounded, ovoid and tapering features.

Age: In old patient the teeth tend to have square form due to attrition, more round features disappears and line angle quite seen in those patients.

Personality: Vigorous type of person have teeth of a size and form with prominent markings, different from those of a delicate appearing woman.

3. Method of pair comparison:-

Allow the patient to select between the same size teeth but different forms. Set two different forms of teeth on the right and left sides of a piece of wax rope, and ask the patients which they prefer.